

Building Vocal Fold Solid Models from CAD models created from MRI/CT scans and Histological data

Scott L. Thomson^{1,2} and Eric J. Hunter^{1,3,4,5}

¹ National Center for Voice and Speech, The University of Utah
Salt Lake City, UT

² Department of Mechanical Engineering, Brigham Young University,
Provo, UT

³ Department of Bioengineering, The University of Utah
Salt Lake City, UT

⁴ Division of Otolaryngology – Head and Neck Surgery, University of Utah School of Medicine
Salt Lake City, UT

⁵ Department of Communication Sciences and Disorders, College of Health, The University of Utah
Salt Lake City, UT

Abstract

Quantification of vocal fold geometry is necessary for the development of anatomically realistic and consistently defined experimental/computational models of the glottic and subglottic regions. Such models will facilitate the study of the influence of the subglottis in voice production. This technical memo is provided primarily as a tutorial for one method for creating physical models from MRI/CT images with histological images as reference. Updates to this memo can be downloaded at <http://www.nrld.org/>.

Keywords: Laryngeal Cartilage, CAD model, MRI, vocal folds

1. Introduction

Understanding the morphology of the laryngeal framework is a crucial step in mapping laryngeal function. Further, accurate dimensions of all structures of the larynx are necessary to produce reliable quantitative biomechanical modeling of voice disorders. Particularly important are dimensions of those structures which describe function in mechanical terms (e.g., laryngeal muscle orientation, cartilage length/width, and joint size/range).

Magnetic Resonance Imaging (MRI) and X-ray computed tomography (CT) scans have become useful tools in obtaining anatomical information in both live subjects and donated samples. In the final form, such images can be used to create geometric shapes. However, there are difficulties with each of these methods. CT only clearly captures boundary distinctions (soft tissue to hard tissue, or tissue to air). On the other hand, MRI can give more tissue variation differences but not at high resolutions. Finally, while histological images achieve better distinction between differing tissue types, the freezing and slicing procedures may introduce some geometric distortion.

With the increased use of these techniques, translating the images to either virtual CAD or physical models is important. The purpose of this report is to discuss a method of creating solid models from MRI, CT and histological images.

2. Histological Image Analysis towards a 2-D Finite Element Model

In this section, we demonstrate the feasibility of generating a finite element mesh using a vocal fold histological section.

Consider the histological section of the vocal fold shown in Fig. 1a where the three layers are distinguishable. The boundary of the three layers was traced with image editing software (e.g. Microsoft Paint), using knowledge of the anatomy and determining the boundary location by adjusting the image contrast (Fig. 1b). In this example, the boundaries approximately corresponded to: (1) the epithelial lining along the medial surface; (2) the interface between the superficial and intermediate lamina propria layers; and (3) the thyroarytenoid muscle boundary. The result is three layers, corresponding to the cover, ligament, and body (muscle).

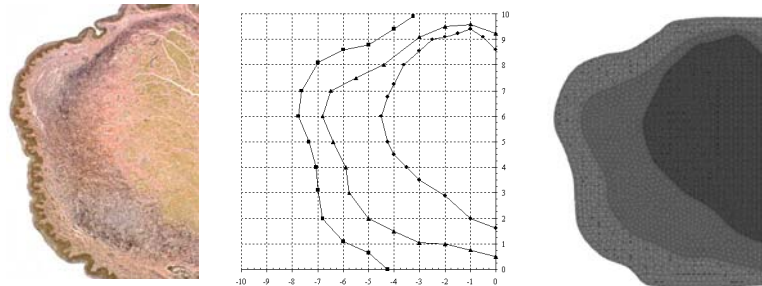


Figure 1: Process of converting histological vocal fold section to finite element model.

To generate a finite element mesh, the point coordinates were entered into the commercial finite element software ADINA (ADINA R&D, Inc., Watertown, MA, www.adina.com), and splines were used to connect the selected points. The three layers were meshed individually, resulting in a three-layer finite element model, shown in Fig. 1c. Extraction of the image data from two to three dimensions using multiple images is a straightforward extension of the MRI-based methods discussed below.

To generate a finite element mesh, the point coordinates were entered into the commercial finite element software ADINA (ADINA R&D, Inc., Watertown, MA, www.adina.com), and splines were used to connect the selected points. The three layers were meshed individually, resulting in a three-layer finite element model, shown in Fig. 1c. Extraction of the image data from two to three dimensions using multiple images is a straightforward extension of the MRI-based methods discussed below.

3. Creating Virtual Models

Virtual Models, or CAD models, are three-dimensional constructs built in CAD software, from which the model can be used in several ways (e.g. imported into a FEM package, loaded into a rapid prototype machine). To create a virtual model from many images, consider a series of histological slides with features extracted as discussed in the previous section. To create the virtual models, point data for each tissue layer (for example, a series of curves defining the thyroarytenoid muscle) can be identified (Figure 2, left).

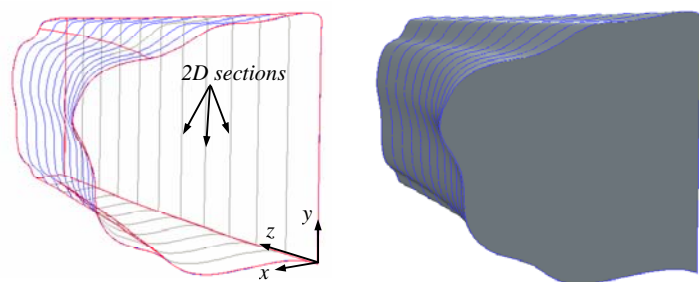


Figure 2: Example of creating three-dimensional virtual model from two-dimensional sections. Left: Series of sections, with each section lying in the x-y plane. Right: Virtual model generated by blending sections

In the example here, these curves were imported into Pro/Engineer and blended together (Figure 2, right). For this particular model, a series of curves was first created. Each of these curves represented a two-dimensional section in the x-y plane; the curves were slightly offset in the z-

direction. Note that the first of these curves (at the $z = 0$ plane) was taken from the histological image analysis shown in Fig. 1a. The curves offset in the z -direction were modifications of the first curve, generated in this case purely for illustration purposes. The curves were imported into Pro/Engineer and a connected virtual three-dimensional model was generated by blending the series of two-dimensional sections. The solid model on the right side of Fig. 2 was then used in modeling or rapid prototyping applications.

Additional detail can then be obtained and included. Consider the series of curves generated using the digitized histological images from Figure 1, which delineates the various tissue layers in the vocal fold. Similar curves can be obtained from each histological (or other) image and imported into Pro/Engineer and converted to three-dimensional virtual models, as was done in Fig. 2. This will yield virtual models of each layer of tissue for each larynx sample. These models, as a whole or part, can be saved in a solid model format (e.g., IGES). The virtual tissue layer models from each larynx sample can then be assembled using Pro/Engineer to create a complete virtual laryngeal model. In Fig. 3, an assembly of three-dimensional virtual models of the vocal fold body, ligament, and cover layers is represented.

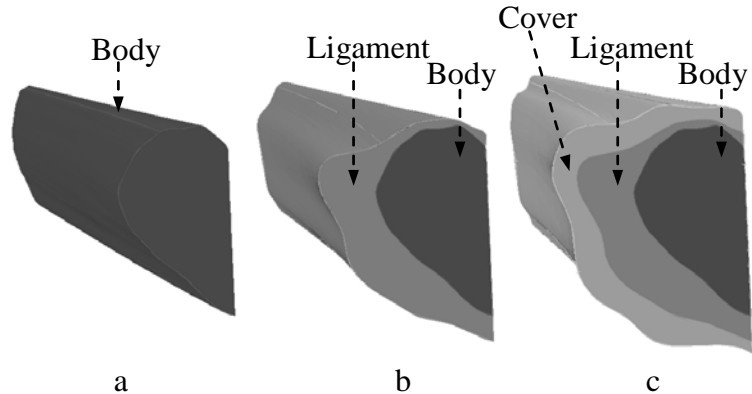


Figure 3: Three-dimensional virtual vocal fold model created from two-dimensional slices. (a) Body layer; (b) Body and ligament layers; (c) Body, ligament, and cover layers.

4. MRI to Solid Modeling

In this section, a series of 128 MRI scans from one human larynx (see NRLD#000001) were used to provide the basic geometry. Using commercial MRI and three-dimensional software packages (Velocity2 and Pro/Engineer, respectively), the images were imported. Grayscale thresholding techniques were used to identify and extract three-dimensional representations of the vocal folds and of the cricoid, thyroid, and arytenoid cartilages. Scaling of the images was conducted using cartilage data from Hunter and Titze (2005). These images and eventual solid models were output as IGES files.

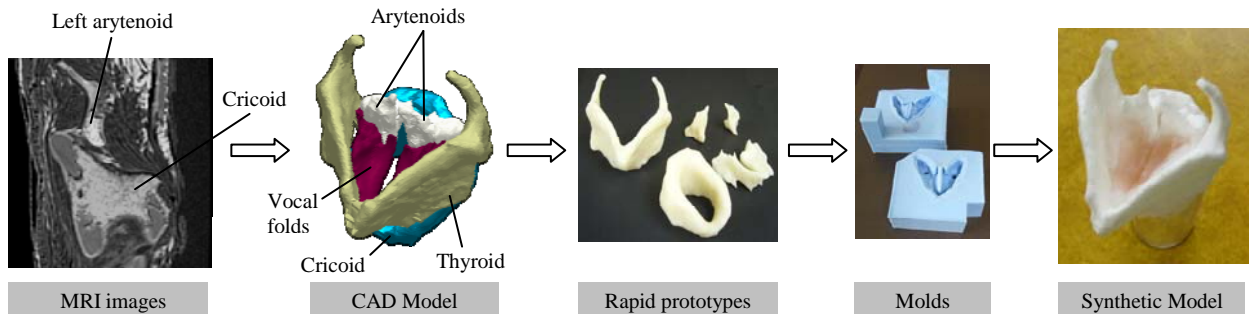


Figure 4: MRI-based synthetic larynx model fabrication process

Physical models of these features were fabricated using a computer-controlled rapid prototyping machine. From these models, molds were constructed. Synthetic models were then created from the molds: cartilage models from liquid plastic, and vocal folds models from liquid silicone. The vocal folds had a Young's modulus of approximately 2 kPa, similar to that of superficial vocal fold tissue layers. The cartilages and vocal folds were fastened together using flexible silicone. The resulting synthetic "joints" were of sufficient stiffness so as to preserve cartilage framework positioning but to allow deformation when acted upon by an external force. A silicone membrane of desired geometry was also attached to simulate the conus elasticus.

5. Additional Notes

Automated boundary extraction techniques (edge detection) do exist but they work best with clear distinctions such as edges of bones and air boundaries. Image segmentation programs, like the free ITK-SNAP (www.itksnap.org), can be used. Other software includes:

Able Software: <http://www.ablesw.com/>

Aracor: <http://www.aracor.com/>

CenPRA (Centro de Pesquisas Renato Archer) (Brazil): <http://www.cenpra.gov.br/promed>

Image3 LLC: <http://www.image3.com/>

Indeed - Visual Concepts (Germany): <http://www.indeed3d.com/>

IVS Solutions AG (Germany): <http://www.ivs-solutions.de/>

Materialise: <http://www.materialise.com/>

Simpleware Ltd. (UK): <http://www.simpleware.com/>

An example of using these types of software in a peer reviewed journal, see Pickup and Thomson (2010).

Literature

- B. A. Pickup and S. L. Thomson. Flow-induced vibratory response of idealized versus magnetic resonance imaging based synthetic vocal fold models, EL124 J. Acoust. Soc. Am. 128 (3) 2010
- S. L. Thomson and E. J. Hunter. Magnetic Resonance Images of Human Laryngeal Cartilage; MRI from Selbie, et al. <http://www.nrl.org/>, NRLD#0000001, vs 1.1, 2011
- W. S. Selbie, S. L. Gewalt, and C. L. Ludlow. Developing an anatomical model of the human laryngeal cartilages from magnetic resonance imaging. J.Acoust.Soc.Am. 112 (3 Pt 1):1077-1090, 2002.

Acknowledgements

We appreciate W. Scott Selbie's help in sharing the initial MRI images as well as his description and guidance. This work was supported by NIDCD grant No DC009616 from National Institutes of Health. The NRLD is supported by the National Institutes of Health (DC009616).

Use Agreement

The scripts, images and text are open to use by the public as a service and part of the National Resource of Laryngeal Data (supported by the National Institute of Deafness and other Communicative Disorders, and hosted by the National Center for Voice and Speech). The scripts, images, model and text enclosed in this memo and accompanying this memo are open to use by the public as a service of the NRLD. However, we ask the reader to respect the time and effort put into this manuscript and research. If the text, images, or included scripts are used, the user agrees to reference to this document, the NRLD, and the source of the original data. We also ask the users to consider contacting the original contributors of the data and give them the right of refusal to (1) participate on papers using the data and (2) have their supporting project acknowledged. The user agrees to freely share with the NRLD any extension software build on the data contained.

Revisions

- 1.0 Eric Hunter: (March 2011) Main document
- 1.1 Eric Hunter: (April 2011) minor edits, title adjustment.
- 2.0 Eric Hunter: (May 2011) Additional content added, software listed.